

Feature Article

The Winner's Article of 2006 Horiba Masao Awards

Development of a System for the Early Diagnosis of Breast Cancer

Masami Ando

We are now developing a system which allows the visualization of the structure and tissue associated with breast cancer, which is difficult to achieve with conventional mammography, by utilizing X-ray refraction. This system is expected to achieve an approximately 1000-fold higher contrast and high spatial resolution at low dose; compared to techniques by use of X-ray absorption. Monochromatic and plane wave X-rays, produced by the diffraction of asymmetric reflection, are applied to the sample, and, corresponding to calcification and tissue structure, X-rays, which is going through slight refraction, are isolated from straight X-rays with an angle analysis plate. With a method called the "X-ray dark field method" which uses a transmission type angle analysis plate, transfer imaging created by refractive X-rays alone can be obtained, making use of the feature that straight X-rays do not go through the angle analysis plate of a certain thickness. Furthermore, a mathematical algorithm concerning refraction contrast was developed to get CT images, and we obtained world's first 3D images of noninvasive ductal carcinoma, etc., based on the refraction principle.

Introduction

This article is on the current status of our attempt to develop a new X-ray imaging system for application to the clinical diagnosis of breast cancer, which utilizes the refraction principle. Due to the increase of morbidity of female breast cancer, it has become a serious social issue, and there has been growing awareness of the importance of early diagnosis. Corresponding to this trend, active efforts have been made, primarily by medical professionals and medical device manufacturers, to develop sophisticated technology for the early diagnosis of breast cancer. Mammography, which uses X-rays, was developed as an example of such technology. What can be visualized by mammography are primarily calcified tissue and the structure of mammary glands. Mammography creates images through detection of the difference in transmittance of X-ray between normal tissue and calcified areas or affected tissue. Technically, differences in X-ray absorption are detected by mammography. Because of these features, the X-ray energy needs to be as low as possible for mammography, resulting in the clinical practice whereby the accelerating voltage of the X-ray device used for mammography is at 30 kV or less and the effective X-ray energy is 20 keV or less.

At the same time, it is necessary to reduce the breast thickness as far as possible and, in practice, the thickness is down to 40-42 mm, as is well known. Thus, relatively low energy X-ray is needed to irradiate breast tissues. Consequently, there is a danger that absorbed dose is high and we need to pay attention to medical exposure. In fact, the breast is known as the part where the skin exposure dose is highest. As an attempt to resolve these issues related to mammography, there appears to be significant in developing a new method of breast cancer diagnosis which uses refractive contrast (known to be about 1000-fold higher than absorption contrast for X-ray of equivalent energy) by utilizing the principle of refraction, while reducing the dose with the use of a slightly higher energy X-ray. We expect that this new method will visualize not only the calcified area but also the structure and tissue associated with breast cancer, which could not otherwise be visualized by any conventional technique. Thanks to the high directivity of synchrotron radiation, there is a possibility that the space resolution rises and allows the visualization of even small calcified areas. We plan to provide a new mammography system as an advanced modality, making use of the principle of refraction, and facilitate the early diagnosis of breast cancer.

On breast cancer, we have pursued development in the synchrotron radiation facility of KEK (High Energy Accelerator Research Organization) and make it possible to provide clear images of the mammary duct, lesions of breast cancer, individual breast cancer cells, groups of necrotic breast cancer cells, radiation quality, etc.. Whether clinical or pathological diagnoses, the development of this technology for the early diagnosis of breast cancer is on the way, though, by introducing the part of the attempt we have made pertaining to this technology, I expect to help readers understand actual state of development and obtain your advice, help and so on.

Studies on the Early Diagnosis of Breast Cancer

The studies on the early diagnosis of breast cancer with synchrotron radiation were started in 1995 using phantoms, and followed by studies on breast cancer tissue. As the radiographic image technology for the visualization of soft tissue, the "absorption contrast technique^[1]", a technique of imaging with reduced X-ray energy, is now routinely used clinically. The "Phase differential contrast^[2]" meanwhile is designed to detect changes in the phase of the X-ray passing through the affected tissue, using an X-ray interferometer and the "Refractive contrast technique^[3]" involves the detection of X-ray refraction within materials, using a crystal angle analysis plate.

Refractive Contrast Method

Now, let's look at refractive contrast. When X-ray reaches the affected area, X-ray is subject to the action of refraction and its course is very slightly deviated from the straight direction. The angle of this deviation is about 10^{-7} rad, equivalent to the angle of viewing a 0.35 mm line imprinted on the decoration at the top of the tower of the Toji Temple from the Kiyomizu Temple Stage located 3.5 km distant from the Toji Temple. Even at such a very minute angle, it is possible to separate the straight X-ray from the refractive X-ray if a silicon single crystal is used. This separation is possible either with method (1); a transmission type angle analysis plate, or with method (2); a reflective type angle analysis plate. Multiple study groups have been involved in the development of each of these two methods. The method (1) is advantageous in that a transmission type angle analysis plate of size equal to that of the region to be tested can be used. In addition,

this technique has another advantage, the capability of getting high contrast images. By utilizing these advantages, this technique will serve as a major technique for X-ray optical systems clinically used in future. The method (2), on the other hand, seems to be difficult to adopt actually, because it requires an angle analysis plate with a size several times larger to obtain a visual field equal to that of the method (1); and two sessions of imaging are needed to obtain refractive information and possibly causing a problem related to the skin exposure dose. Despite these disadvantages, the method (2) has been adopted worldwide because of the simplicity of the X-ray optical system involved.

We have been engaged in technology development on two X-ray optical systems applicable to different objectives. For (A); mammography which utilizes two-dimensional images, we adopted the method (1) as a means of clinical diagnosis and certain pathological diagnosis. For us, transmission type was more natural, since we have started from the utilization of an X-ray interferometer. The greatest advantage of this method is the capability of getting high contrast pictures immediately. For (B); the development of systems targeting pathological diagnosis using biopsy specimens or surgical specimens, we have decided to adopt the method (2) for the time being, since we do not have to mind the dose and, for applying method (1) to (B), additional technological development is required.

X-ray Dark Field Method

In the course of exploring new X-ray optical systems utilizing X-ray interferometers, our theoretical analysis revealed that X-rays could not transmit across angle analysis plates of a certain thickness. This phenomenon may be explained by the same principle underlying glasses coated with an antireflective coat of a certain thickness to protect eyes from dazzling. Because refractive X-rays enter the angle analysis plate at a different angle, they can transmit across the plate. By utilizing this principle, it should be possible to get images made of refractive X-ray only, that is, it would be possible to achieve efficient imaging of human soft tissues, such as cancers. This method suppresses the illuminating light intensity and extracts only the desired visual information. Because of these features, we named it "X-ray dark field method (Figure 1)^[4]". It was discovered in the year, 2002.

The X-ray dark field method is an application of two-crystal monochromator technology. Its characteristic is that diffraction planes of both the monochromator and the

transmission type angle analysis plate are parallel. The diffraction plane of the monochromator, made of the first crystal, is not parallel to the surface but has some angle to it. This is called "asymmetric reflection", an idea created in 1962 by Prof. Kazutake Kohra, who taught me during graduate school^[5]. By utilizing this, the reflective X-ray assumes the form of a flat wave.

The X-ray optical system used for the X-ray dark field method with a wide visual field is a two-crystal parallel arrangement consisting of a monochromator and a transmission type angle analysis plate. If the diffraction plane inclined from the crystal surface is used, the X-ray applied to the sample assumes the form of flat wave. The sample is placed between the monochromator and the transmission type angle analysis plate. Only the refractive X-ray from the sample can reach the posterior side of the plate. The transmission type angle analysis plate used for clinical diagnosis has a thickness of 2.124 mm and the visual field is 90 x 90 mm.

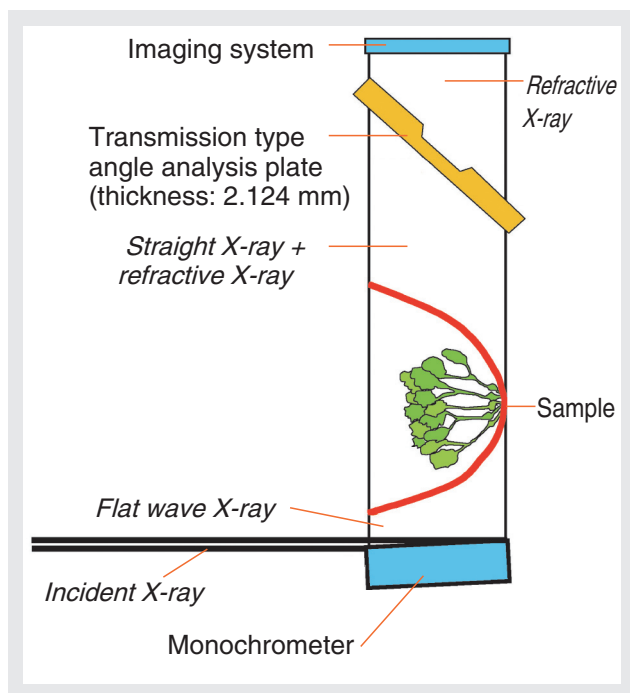


Figure 1 X-ray dark field optical system with a wide visual field

A part of the X-ray entering the affected tissue undergoes refraction and can pass through the angle analysis plate. That is, the refractive X-ray from the affected tissue forms an X-ray dark field image. This image is considered not to be under the influences of illumination. In view of "clinical applications" expected in the near future, we attempted to expand the visual field using this technique, and have achieved a visual field of 90 x 90 mm. The spatial resolution was 50 μm when the thickness was 2.124

mm and the X-ray energy was 35 keV. However, this spatial resolution is an estimate (not an actually measured value) since no phantom for refractive contrast assessment is available. Then, we are making a phantom for this purpose and if this becomes available, more precise determination of spatial resolution will be possible. When the thickness of the angle analysis plate was 125.6 μm , the spatial resolution became higher (about 10 μm). This is also an estimate and the visual field at that time was 10 x 10 mm.

Our Motivation for Development

The method (1); "X-ray dark field method using a transmission type angle analysis plate", presented in the Chapter "Studies on the Early Diagnosis of Breast Cancer" is fit for the use in obtaining two-dimensional images. We will endeavor to develop a new system for clinical diagnosis making use of this method. On the other hand, the method (2); "a method using a reflective type angle analysis plate"; is suitable for obtaining three-dimensional images. We will verify the extent to which pathological diagnosis with staining is possible if this method is used. If three-dimensional imaging with the X-ray optical system of the method (1) is possible, the diagnostic capability will be increased, due to the availability of not only two-dimensional but also three-dimensional images getting from the X-ray optical system of the method (1). Now let's discuss two-dimensional and three-dimensional images of breast cancer.

Two-Dimensional Images of Breast Cancer

As an example of the X-ray dark field imaging, we challenged the imaging of invasive papillary microcarcinoma. In this challenge, we could observe normal tissue, groups of breast cancer cells, fat layers, muscles, fibers, and so on (Figure 2)^[6]. Mammography with the X-ray dark field method allows high contrast and spatial resolution and is expected to have a higher diagnostic capability and facilitate the early diagnosis of breast cancer.

In the imaging of the X-ray dark field, the colors, black/white, are inverse to the colors of the absorption contrast. The black area in Figure 2 consists of refractive X-ray, and the same area is white on the absorption contrast

image. The grey area in the same figure indicates the X-ray-free area and is depicted as a black area with the absorption contrast. The sensitivity of refractive contrast is about 1000 times that of the absorption contrast (the finding within the white line will be discussed later).




Figure 2 X-ray dark field image of the sample of 2.8 mm thick invasive ductal microcarcinoma (35 keV)

The image taken with this technique was found to correspond well to the picture of the pathologic specimen after Hematoxylin and Eosin staining^[6]. The composition of the sample constituting the contrast visible on the X-ray dark field image was analyzed by fluorescence analysis. A white X-ray was applied to the specimen, using a HORIBA XGT-5000WR with an Rh target. The Ca K X-ray from the specimen was then subjected to pulse-height analysis, using a semiconductor detector and the specimen was then subjected to two-dimensional scanning. Accordingly, a Ca K fluorescent X-ray image, resembling the X-ray dark field image well, was obtained (Figure 3)^[7]. This may be viewed as a good example

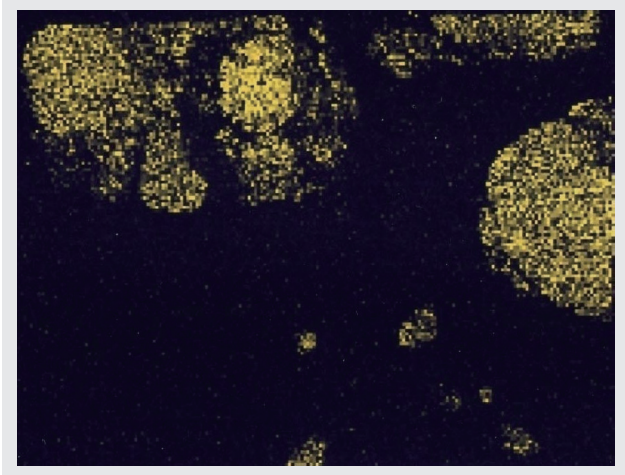


Figure 3 Ca K fluorescent X-ray image

indicating the relationship between breast cancer and Ca. The Ca K X-ray is absorbed even by soft tissue with small thickness (slightly less than 20 μm). This X-ray image may reflect calcification in the very superficial area of the specimen.

Figure 4 is an X-ray dark field image of the area within the white frame in Figure 2, using a thinner transmission type angle analysis plate^[8]. The cancer cell nests are visible in the center and to the right of the image. Tens to more than a hundred bubble-like structures are noted slightly left above the center, which probably represent breast cancer cells. The size of each cell appears to be about 100 μm. Stroma is also visible. The spatial resolution is estimated at 10 μm.

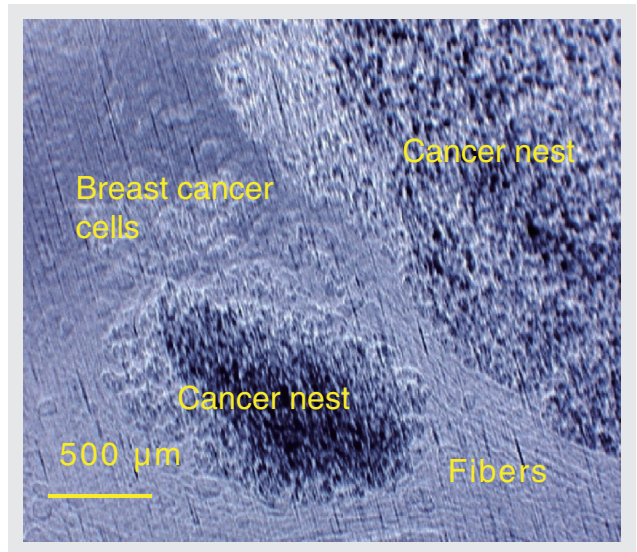


Figure 4 High spatial resolution X-ray dark field image taken with a 125.6 μm thick transmission type angle analysis plate

Individual breast cancer cells are visible around the central nest of cancer cells, individually about 100 μm in size. Stroma is visible between the cell nests.

Three-Dimensional Images of Breast Cancer

A mathematical algorithm on refractive contrast was developed to obtain CT images. Using this algorithm, three-dimensional images of noninvasive ductal carcinoma, etc., have been obtained on the basis of the principle of refraction with a spatial resolution of 50 μm, as the world first^[9-11]. The algorithm on refractive contrast is shown by Formula(1)^[12-16].

$$a(\Theta, t) e^{i\Theta} = \int_s |\nabla \tilde{n}| e^{i\phi} ds \dots\dots\dots (1)$$

Feature Article

Development of a System for the Early Diagnosis of Breast Cancer

Here, α indicates the refractive angle, Θ indicates the angle of sample rotation, t is the coordinate perpendicular to the direction of the beam course, \tilde{n} is the term related to the index of refraction n ($n = 1 - \tilde{n}$), and ϕ indicates the angle formed by $\nabla\tilde{n}$ and the propagation vector S . Formula(1) was developed by Dr. MAKSIMENKO Anton (currently a member of our laboratory) during his thesis research for a degree in Graduate University for Advanced Studies under guidance by Prof. Tetsuya Yuasa in Yamagata University.

Another X-ray optical system is illustrated in Figure 5. In terms of basic architecture, this system resembles the X-ray optical system shown in Figure 1. The system shown in Figure 1 uses a transmission type angle analysis plate, while that in Figure 5 has a reflection type angle analysis plate.

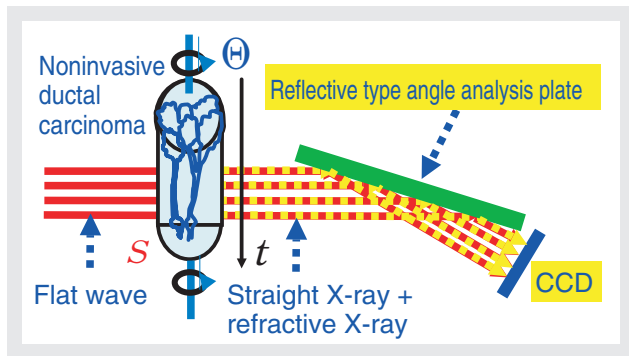


Figure 5 X-ray optical system for acquisition of refractive CT data

The sample rotation axis is perpendicular to the paper surface and a refractive X-ray is obtained from the sample exposed to the flat wave. A straight X-ray meanwhile, undergoing no change in angle, overlaps on the refractive X-ray and the angular component of the refractive X-ray is extracted by the reflective type angle analysis plate. The image for each sample rotation is fed into the CCD.

When this technique was applied to noninvasive ductal carcinoma with a diameter of 3.5 mm and a length of 4.5 mm, a three-dimensional image as shown in Figure 6 was obtained^[9]. The mammary duct, calcification within the mammary duct, and fibrous connective tissue and fat around the mammary duct are all clearly visible. The image provides a three-dimensional view in which the three mammary ducts close to the lower end of the image become a single duct in the upper part.

Figure 6 is a composite image obtained with Formula (1). The area resembling thin silk is the mammary duct, while the white area, assuming the form of an icicle within the mammary duct, indicates calcification. The two large

mammary ducts meanwhile, with a sign of calcification, join to form a single duct in the upper part of the image. The left duct is composed of 3 joining ducts, and the right duct is composed of 2 joining ducts. Necrotic breast cancer cells may be present in the junction.

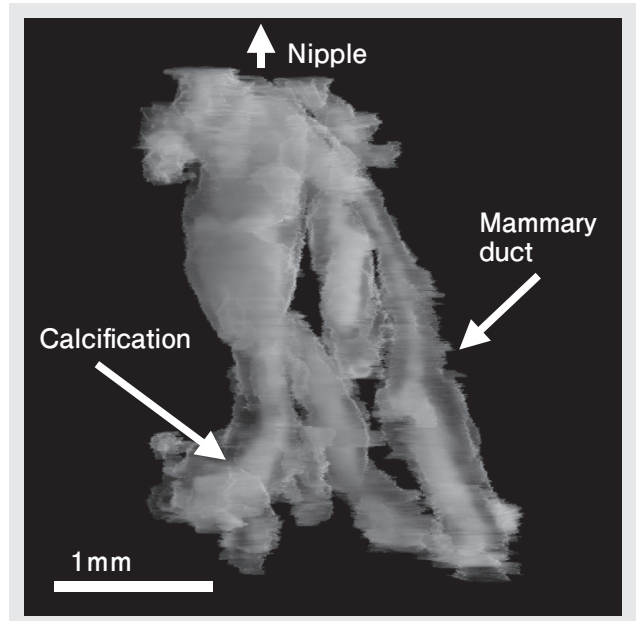


Figure 6 Three-dimensional image of noninvasive ductal carcinoma

In conventional pathological diagnosis using staining, the creation of three-dimensional images from biopsy specimens is seldom attempted because it takes a lot of troubles. Instead, pseudo three-dimensional images can be obtained by combining two-dimensional slice images of tissue, however, this cannot be done routinely since it takes a lot of time. Thus, three-dimensional images have rarely been available for this kind of diagnosis. The three-dimensional images of mammary ducts presented in this article are those obtained as the world first.

Conclusion


Two-dimensional and three-dimensional X-ray imaging techniques are promising as a new means for the clinical diagnosis of breast cancer in the near future. We expect these techniques to be available as new systems making use of synchrotron radiation. We also expect these techniques to be applicable not only to breast cancer but also to lung, pancreas and liver cancers, and so on. I really hope that the early diagnosis of these cancers be facilitated seriatim as early as possible.

Acknowledgments

The research presented in this article was financially supported under "Grant-in-Aid for Exploratory Research" (#15654042, 2003-2005) and "Grant-in-Aid for Scientific Research (A)" (#18206011, 2006-2008). The utilization of synchrotron radiation was promoted within the framework of the adopted KEK study projects #2002G045 and #2005G085. The research was carried out jointly with the following researchers: T. Akatsuka (Yamagata University), M. Ishiguro (Institute of Statistical Mathematics), S. Ichihara (National Hospital Organization Nagoya Medical Center), E. Ueno (Tsukuba University), T. Endo (National Hospital Organization Nagoya Medical Center), C. Obayashi (Kobe University), T. Kawai (Hamamatsu Photonics), T. Kimura (Kobe University), T. Saito (Tohoku Bunka Gakuen University), D. Shimao (Ibaraki Prefectural University of Medical Sciences), H. Sugiyama (High Energy Accelerator Research Organization), Y. Chikaura (Kyushu Institute of Technology), S. Cho (High Energy Accelerator Research Organization), F. Toyofuku (Kyushu University), S. Nishikawa (HORIBA, Ltd.), E. Hashimoto (Graduate University for Advanced Studies), H. Bando (Tsukuba University), K. Hirano (High Energy Accelerator Research Organization), M. Hirano (Niihama National College of Technology), K. Hyodo (High Energy Accelerator Research Organization), MAKSIMENKO Anton (High Energy Accelerator Research Organization), K. Yamazaki (Kobe University) and T. Yuasa (Yamagata University). I would like to show my appreciation for these people.

Reference

- [1] E. Burattini, E. Cossu, C. Di Maggio, M. Gambaccini, P. L. Indovina, M. Marziani, M. Pocek, S. Simeoni and G. Simonetti, *Radiology*, **195**, 239 (1995).
- [2] T. Takeda, J. Wu, Y. Tsuchiya, A. Yoneyama, T. T. Lwin, Y. Aiyoshi, T. Zeniya, K. Hyodo and E. Ueno, *Japanese Journal of Applied Physics*, **43**, 5652 (2004).
- [3] S. Fiedler, A. Bravin, J. Keyrilainen, M. Fernandez, P. Suortti, W. Thomlinson, M. Tennunen, P. Vriikunen and M.-L. Karhalainen-Lindsberg, *Physics in Medicine and Biology*, **49**, 175-188 (2004).
- [4] Ando, M., Maksimenko, A., Sugiyama, H., Pattanasiriwisawa, W., Hyodo, K. and Uyama, C., Simple X Ray Dark- and Bright- Field Imaging Using Achromatic Laue Optics., *Japanese Journal of Applied Physics*, **41**, L1016-L1018 (2002).
- [5] Kohra, K., *Journal of the Physical Society of Japan*, **17**, 589 (1962).
- [6] Ando, M. et al, Attempt at Visualizing Breast Cancer with X-ray Dark Field Imaging, *Japanese Journal of Applied Physics*, **44**, L528-L531 (2005).
- [7] Ando, M. et al, Attempt at 2D Mapping of X-ray Fluorescence from Breast Cancer Tissue, *Japanese Journal of Applied Physics*, **44**, L998-L1001 (2005).
- [8] Ando, M. et al, Sharper Image of Breast Cancer Cells and Stroma in the Dense Breast by Thinner Angular Filter under X-Ray Dark-Field Imaging, *Japanese Journal of Applied Physics*, **45**, L740-L743 (2006).
- [9] Ando, M., D and 3D Visualization of Ductal Carcinoma in situ (DCIS) due to X-Ray Refraction Contrast, *Bioimages*, **13**, 1-7 (2005).
- [10] Hashimoto, E., Maksimenko, A., Sugiyama, H., Hyodo, K., Shimao, D., Nishino, Y., Ishikawa, T. and Ando, M., First application of x-ray refraction based computed tomography to a biomedical object, *Zoological Science*, **23**, 809-813 (2006).
- [11] Ando, M. et al, under review.
- [12] Maksimenko, A. et al, Computed Tomographic Reconstruction Based on X-Ray Refraction Contrast, *Applied Physics Letters*, **86**, 124105 (2005).
- [13] Maksimenko, A. et al, On the possibility of the computed tomographic reconstruction of cracks from the X-ray refraction contrast, *Japanese Journal of Applied Physics*, **44**, L633-L635 (2005).
- [14] Yuasa, T., Sugiyama, H., Zhong, Z., Maksimenko, A., Dilmanian, F. A., Akatsuka, T. and Ando, M., High-Pass Filtered Diffraction Micro - Tomography by Coherent Hard X-rays for Cell Imaging: Theoretical and Numerical Studies of the Imaging and Reconstruction Principles, *Journal of the Optical Society of America A*, **22**, 2622-2634 (2005).
- [15] Yuasa, T., Maksimenko, A., Hashimoto, E., Sugiyama, H., Hyodo, K., Akatsuka, T. and Ando, M., Hard-X-Ray Region Tomographic Reconstruction of the Refractive-index Gradient Vector Field: Imaging Principles and Comparisons with Diffraction-Enhanced-Imaging-Based Computed Tomography, *Optics Letters*, **31**, 1818-1820 (2006).
- [16] Yuasa, T. et al, under review.



Masami Ando

Tokyo University of Science
 DDS Research Center
 Research Institute for Science and Technology
 Professor
 Ph.D. in Engineering